

LETTER TO THE EDITOR

THIOACETAMIDE TOXICITY AND THE LUNG :  
HISTOLOGICAL ANALYSIS

Sir,

(Received on February 10, 2002)

Selenium is a naturally occurring micronutrient and trace element that has a narrow margin between beneficial and harmful levels. The role of selenium when administered in carefully titrated doses was studied on thioacetamide induced experimental liver cirrhosis. Ethical clearance from the Institutional Animal Ethics Committee was obtained.

Thioacetamide (TA) is one of the several agents that produce centrilobular necrosis of the liver and has been so employed. The effects of TA are not limited to the liver as profound structural and functional changes have been described in the kidney (1), thymus (2), spleen (3) and the intestine (4). These modifications may alter the response seen in the liver and influence the host response in general. The following report concerns the response of the lung to this agent.

Healthy male albino rats of Wistar strain (100-200 g) were maintained in our animal house on standard laboratory diet and water *ad libitum* for 1 week prior to experimentation. The animals were kept in individual plastic cages with natural light and dark cycles and a temperature of  $28 \pm 4.0^\circ\text{C}$ . The duration of the study was 16 weeks. The animals were divided into four

groups. Group 1 (n = 10) continued to be on food and water *ad libitum* and served as control. Group 2 (n = 10) received TA (0.3 g/L) of drinking water (5, 6) and food *ad libitum* for 16 weeks. Group 3 (n = 10) rats received TA (0.3 g/L) and sodium selenite (4 mg/L) of drinking water (7) and food *ad libitum* for 16 weeks. Group 4 (n = 10) received TA (0.3 g/L) of drinking water for the first 8 weeks and sodium selenite (4 mg/L) of drinking water for the latter 8 weeks with food *ad libitum* for the duration of the study. The fluid intake in ml was measured daily and the body weight in grams (g) was measured once a week. At the end of the study, all the animals were anesthetized with diethyl ether. The abdomen and thorax were opened by a midline incision. The liver, spleen, kidneys and lungs were identified, removed, blotted and weighted promptly. Biopsy bits from liver, spleen, kidney and lung of rats belonging to all the groups were fixed in 10% formalin overnight. Tissue sections of 2-3 mm thickness were dehydrated in alcohol, cleared in xylene and tissue blocks were made in the paraffin wax. Sections of 5  $\mu$  thickness were cut, dewaxed in xylene, rehydrated and stained with haematoxylin and eosin. Stained sections were studied under light microscope after mounting in D.P.X. (Distrene Dibutylphthalate) (8).

In contrast to the profound structural and functional changes that were described in the kidney (1) and spleen (3), no histological changes were found in these organs in this study. Sections from lungs of all rats belonging to groups 2 and 3 showed focal interstitial pneumonia. Alveolar walls were thickened due to oedema, mild fibrosis and inflammatory cell infiltration by lymphocytes and plasma cells. Many air spaces were distorted and obliterated due to both oedema fluid and macrophages and other air spaces were cystically dilated (Fig. 1). Sections from the liver of all rats

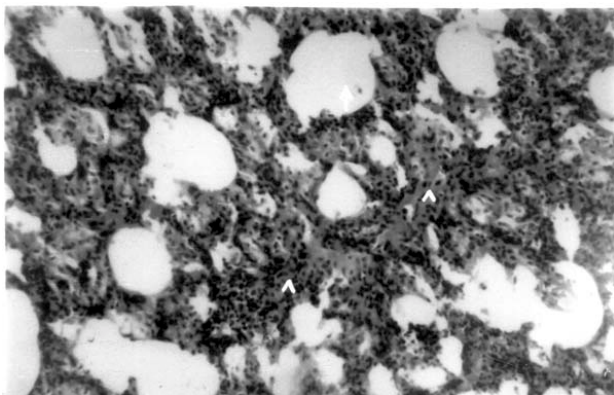
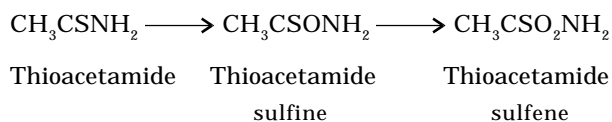


Fig. 1: Section of the lung showing thickened alveolar walls due to oedema, mild fibrosis and inflammatory cell infiltration by lymphocytes and plasma cells (arrow head). Many air spaces are distorted and obliterated due to both oedema fluid and macrophages and other air spaces are cystically dilated (arrow) H and E  $10 \times 100$ .

belonging to groups 2 and 3 showed cirrhosis with or without dysplasia (one section showed evidence of cholangiocarcinoma). There was a decrease in the mean weight of the lung and liver of animals in groups 2 and 3 versus group 1 (control) that was statistically significant at  $P < 0.05$  using analysis of variance and Dunnett's test there

after. A 20% and 10% mortality in groups 2 and 4 respectively was noted in the course of the study, (sections of the liver of the rat in group 4 that died in the 7th week of the study, showed evidence of cirrhosis). The remaining animals that survived in group 4 showed no histological evidence either of liver cirrhosis or focal interstitial pneumonia. Animals in groups 2, 3 and 4 that received thioacetamide showed decreased activity and bristling of fur but otherwise ate and drank in a manner similar to the controls.

It seems clear that two not necessarily exclusive possibilities may explain the basis of the alveolar lesion of focal interstitial pneumonia resulting from TA ingestion. A direct toxic injury of the alveoli by TA or its toxic metabolites (9) as TA is extensively metabolised during its passage through the body (10) may explain the toxicity to a select population of cells (1).



Secondly opportunistic infection due to decreased immunity because of toxic injury to cells of immune system (2). Interstitial pneumonia is caused by a wide variety of agents such as respiratory syncytial virus, influenza, parainfluenza virus, cytomegalovirus, adenoviruses, rhinoviruses and coxsackie viruses (11). Infection of the upper respiratory tract with these organisms are quite common. Occasionally infection extends lower down to involve the interstitium of the lungs. Circumstances favouring such extension of infection arise

from decreased immunity which predisposes various organs to infection by opportunistic organisms. The significance of this chemically induced lung lesion in TA toxicity remains to be identified.

Animals that received sodium selenite along with TA showed evidence of liver

cirrhosis with no mortality. Animals that received sodium selenite after TA showed evidence neither of liver cirrhosis nor mortality (except one). These observations help us to conclude that selenium in carefully titrated doses mitigates the damage in experimentally induced liver cirrhosis.

LATHA M. S.\*, MIRABEL RSM PAI\*\*  
AND PUSHPALATHA PAI K.\*\*\*

*Department of \*Pharmacology,  
Army College of Dental Sciences,  
Mercury Lines, Trimulgherry,  
Secunderabad – 500 015*

and

*Departments of \*\*Pharmacology and \*\*\*Pathology,  
Kasturba Medical College,  
Mangalore – 575 001*

## REFERENCES

1. Barker EA, Smuckler EA. Non hepatic thioacetamide injury. 11 The morphologic features of proximal renal tubular injury. *Am J Pathol* 1974; 74: 575–583.
2. Barker EA, Smuckler EA. Non hepatic thioacetamide injury. 1 Thymic cortical necrosis. *Am J Pathol* 1973; 71: 409–416.
3. Al-Bader A, Mathew TC, Koursheed M et al. Thioacetamide toxicity and the spleen : histological and biochemical analysis. *Anat Histol Embryol* 2000; 29(1): 3–8.
4. Ortega MA, Torres MI, Fernandez MI et al. Hepatotoxic agent thioacetamide induces biochemical and histological alteration in rat small intestine. *Dig Dis Sci* 1997; 42(8): 1715–1723.
5. Dashti H, Mathew TC, Jadaun MM, Ashkanani E. Zinc and liver cirrhosis : biochemical and histopathologic assessment. *Nutrition* 1997; 13(3): 206–212.
6. Al-Bader AA, Mathew TC, Abul H et al. Bacterial translocation in thioacetamide induced liver cirrhosis in rats. *J R Coll Surg Edinb* 1998; 43: 278–282.
7. Dashti HM, Abul H, Behbehani A et al. Interleukin 8 and trace elements alteration in experimentally induced liver cirrhosis : the influence of zinc, selenium and allopurinol treatment. *J Trace Elem in Exp Med* 1996; 9: 27–40.
8. Sood R. Histopathology in Medical Laboratory Technology Methods and Interpretations. 4th edn, New Delhi : Jaypee Brothers, 1994; 586–593.
9. Hunter AL, Holscher MA, Neal RA. Thioacetamide induced hepatic necrosis. 1 Involvement of the mixed function oxidase enzyme system. *J Pharmacol Exp Ther* 1977; 200: 439–448.
10. Nygaard O, Eldjarn L, Nakker KF. Studies on the metabolism of thioacetamide <sup>35</sup>S in the intact rat. *Cancer Res* 1954; 14: 625–628.
11. Harsh Mohan MD. Viral and mycoplasma pneumonia in the respiratory system. In Textbook of Pathology. 3rd edn, New Delhi : Jaypee Brothers, 1998; 530–531.

---

\*\*Corresponding Author : Visiting Professor, Tulane Medical Center, Department of Pharmacology, Tulane University School of Medicine, 1430 Tulane Avenue, New Orleans, LA 70112, USA.